

ORIGINAL ARTICLE

Shaban Mohamed Mourtaga, Samir M Kuhail* Mohammed A. Tulaib.

Foreign Body Inhalations Managed by Rigid Bronchoscope Among Children, in Shifa Hospital - Gaza, Palestine.

Abstract

Purpose: To highlight foreign body (FB) inhalation and management by rigid bronchoscope in ENT department at Shifa hospital (Gaza-Palestine). **Methods:** 150 cases were referred to ENT evaluation for possible FB inhalation, 104 (69.3%) with history of FB inhalation and 46 (30.7%) with history of respiratory illnesses. Patients studied aged 1 month to 8 years. Male/female ratio was 63.3/36. **Results:** 88 (58.7%) of the cases presented with positive foreign body. Resting site(s) of foreign body: 3 (3.4%) cases presented with foreign bodies in the subglottis, 14 (15.9%) in trachea, 46 (52.3%) in right main bronchus, and 25 (28.4%) in left main bronchus. Types of foreign bodies observed: 35 (39.8%) patients examined had water melon seeds, 35 (39.8%) had bean, 14 (15.9%) had food particles, and 4 (4.5%) had plastic particles. The majority of patients treated had complete removal of FBs: 147 (98%) from the first intervention with bronchoscope and the rest FBs required a second intervention. No mortalities occurred amongst patients during the course of this study. **Conclusion:** rigid bronchoscope is a potentially safe and effective procedure for foreign body removal from the respiratory tract.

Introduction:

Aspirated foreign bodies may remain undetected and cause serious complications in affected patients. In 1936 death rate related due to foreign body inhalation was 24% worldwide, using endoscopes to remove foreign bodies lowered the mortality rate to 2%. According to the US national safety council the mortality rate due to FB inhalation is 1.2 per 100,000 people per year (1, 2).

Foreign bodies of the tracheo-bronchial tree occur mainly in children, particularly in those under 2 years of age. The right bronchus is the site of predilection for foreign bodies because the carina is slightly to the left of the midline, the right bronchus is wider than the left, and the right bronchus has more direct extension of the trachea than the left bronchus⁽³⁾. Sisenda concluded that the FBs in the tracheo bronchial tree are a major cause of morbidity and mortality in children aged below 10 years, and its mortality rate is 3.3%⁽⁴⁾.

Types of foreign bodies observed in the clinic are divided into organic and non-

organic. Organic FB cause rapid and severe inflammatory reactions in the respiratory tract. In the case of peanut aspiration, after a latent period of approximately 24 hours, the patient develops productive cough of purulent sputum and fever. Non organic FB that cause partial obstruction of a bronchus may be tolerated for long periods and may lead to formation of granulation tissue. Aspirated solid or semisolid object may lodge in the larynx or trachea. If the object is large enough to cause nearly complete obstruction of the airway, asphyxia may rapidly cause death. Lesser degrees of obstruction, can result in less severe signs and symptoms⁽²⁾.

Clinical presentations of foreign bodies depend on: (1) Size, shape and character of FB, (2) age of patient, (3) duration the FB had been present and (4) location of the FB.

Management of foreign body inhalation depends on the site of foreign body: Laryngeal and subglottic foreign body need urgent management with rigid bronchoscope or urgent tracheotomy. Tracheal FBs may

produce little or no respiratory distress and then suddenly becomes impacted in the subglottic area. With the introduction of the bronchoscope, they can be bypassed or displaced into the distal portion of the trachea. With bulky tracheal FBs, it may be necessary to bypass the FB with the bronchoscope and insert it into a bronchus to ventilate the patient. Most bronchial FB do not present a need for urgent intervention, and one may take time to prepare the patient optimally and gather the items of equipment that might be particularly useful in the problem at hand. in patient with FB^(5,6).

The Purpose of this study was to highlight foreign body (FB) inhalation and role of rigid bronchoscope in its management in ENT department at Shifa hospital in Gaza, Palestine.

Methods:

The study was a retrospective clinical review of archived patients' records from January 1, 2000 to December 31, 2000 in the ENT department at Shifa Hospital. Shifa hospital is the largest general governmental hospital in the Gaza Strip (1,300,000 population). The target population consisted of children from both sexes who were admitted to the hospital and underwent rigid bronchoscope due to FB inhalation, suspected FB inhalation or referral for bronchoscope evaluation due to other medical causes.

These cases which were managed by rigid bronchoscope in the ENT department at Shifa hospital, comprised children aged 1 month to 8 years old, admitted during the period from January 1, 2000 to December 31, 2000. The total number of cases eligible for inclusion in this study was 150. The following procedure was followed during this study: (1) The names of the target population were obtained from the operation

room registry and ENT department. (2) The archived records of listed patients were reviewed. (3) Data were abstracted in a data collection form. (4) Revision and processing collected data analysis and final report were performed.

Bronchoscope was categorized as emergency and elective, 140 (93.3%) cases had elective bronchoscope, and only 10 (6.7%) had emergency bronchoscope.

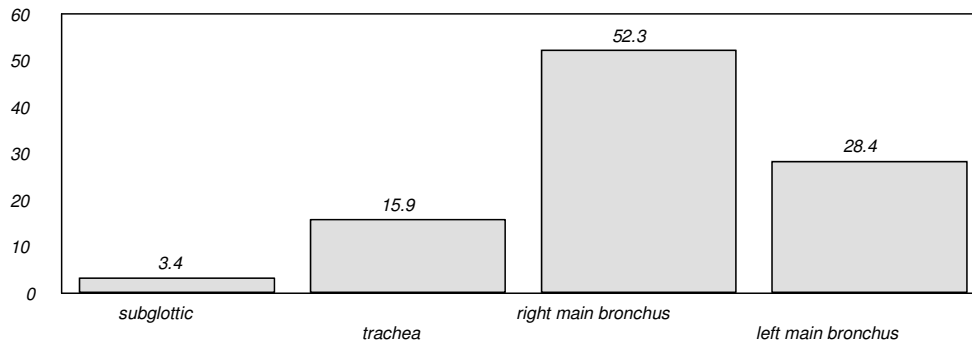
Results:

Number of cases examined was 150 cases referred for ENT evaluation for possible FB inhalation. Of the cases examined 104 (69.3%) had a history of FB inhalation and 46 (30.7%) had a history of respiratory illnesses, ages ranged from 1 month to 8 years, distributed as follows: 40 (26.7%) cases aged 1 - 12 months, 77 (51.3%) cases aged 1- 3 years, 33 (22%) aged above 3 years. Male/females ratio was 63.3/36.7 (1.7).

X-Ray findings: all patients had chest X ray and 51 (34%) cases had no detectable abnormality (NDA), 19 (12.7%) cases had localized collapse (LC), 57 (38%) cases had localized hyperinflation (LH), and 23 (15.3%) of children had inflammatory reaction (IR).

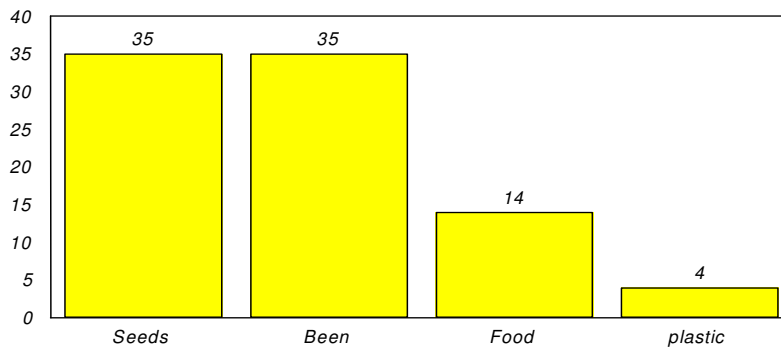
Bronchoscope findings for foreign Bodies (FBs): 88 (58.7%) cases had positive foreign body finding, 29(19.3%) cases had no foreign body, and 33 (22.0%) cases had other results.

Anatomical site of the foreign body: 3 (3.4%) cases had FBs with subglottic localisation, 14 (15.9%) had FBs with tracheal localisation, 46 (52.3%) had foreign bodies in the right main bronchus, and 25 (28.4%) cases had foreign bodies in the left main bronchus (Figure 1).

Figure 1. Resting sites of inhaled foreign bodies

Types of foreign bodies observed with bronchoscopy: 35 cases presented with water melon seed(s) inhalation, 35 cases

with bean inhalation, 14 with food particle inhalation and 4 with plastic particle inhalation (Figure 2).

Figure 2. Type of foreign body

Relationship between history of FB inhalation and bronchoscope results: Bronchoscopy detected 77 (73%) positive cases with history of FB inhalation and 11 (24%) positive cases of pulmonary diseases with no history of FB inhalation. Bronchoscopy showed negative results for F-B inhalation in 22 (21.1%) cases with positive history of F-B inhalation and 7 (15.2%) cases with negative history of foreign body inhalation. Bronchoscopy at

Shifa hospital missed 5 (5.8%) positive cases with positive history of FB inhalation and 28 (60.9%) cases with negative history of FB inhalation. Total positive cases diagnosed with bronchoscopy at Shifa hospital were 88 (58%), total negative cases were 29 (19.3%), and diagnosis 33 (22.7%) positive cases was missed. The bronchoscopy findings are summarized in (Table 1).

Table 1. History of FB inhalation related to bronchoscope result .

MEDICAL HISTORY OF FB INHALATION						
Bronchoscope	Positive		Negative		Total	
	No.	%	No.	%	No.	%
Positive	77	73	11	24	88	58
Negative	22	21.1	7	15.2	29	19.3
Missed diagnosis	5	5.8	28	60.9	33	22.7
Total	104	69.3	46	30.7	150	100

X-Ray findings by bronchoscope results: The x-rays of all cases presenting with

positive bronchoscope FBA showed that: 32 (36.4%) cases had NDA, 7 (8%) cases

LC, 39 (44.3%) cases LH, and 10 (11.4%) IR. The x-rays of all cases presenting with negative bronchoscope of F.B showed that: 13 (44.8%) cases had NDA, 1 (3.4%) case LC, 14 (48.3%) LH, and one (3.4%) case

had IR. X-rays for other, non-FBA, findings diagnosed with bronchoscopy: 6(18.2%) showed NDA, 11 (33%) had LC, 4 (12.10%) LH, and 12 (36.4%) IR (Table 2).

Table 2. X-ray related to bronchoscope results

BRONCHOSCOPE RESULTS							
X-ray	Positive		Negative		Other		Total
	No.	%	No.	%	No.	%	
NDA	32	36.4	13	44.8	6	18.2	51
LC	7	8	1	3.4	11	33	19
LH	39	44.3	14	48.3	4	12.1	57
IR	10	11.4	1	3.4	12	36.4	23
Total	88	58.7	29	19.3	33	22	150

Prognosis: The majority of patients (147 [98%]) completely recovered whilst few (3 [2%]) cases developed complications in the form of intolerance to the procedure and referred to the intensive care unit for 3 to 4 days. No mortalities were observed in this study.

Discussion and Conclusions:

Management of foreign body inhalation at Shifa hospital enjoyed still enjoys success with minimal complications. This is so due to several factors including prompt seeking of medical advice by the child's family, early management and proper intervention. All these factors result in successful intervention with little complications. i.e. They also allow the child to tolerate the bronchoscopic intervention and consequently prevent deterioration of the affected child's condition leading to minimization of complications and mortality. Our study showed similar results to those obtained by Kosloske who had successful bronchoscope extractions of foreign bodies from about 98% managed⁽⁷⁾.

Brown and Clark, (1983) reported that foreign body inhalation occurs primarily between the ages of 1 and 3 years⁽⁵⁾ In this study the majority cases related to children aged less than 3 years (78%) . Wasyle Szeremeta reported that the most commonly observed sites of FBs were in the right bronchus 67%, left bronchus 37%, trachea 3% and larynx 2%⁽⁸⁾. This study showed that right main

bronchus was the most commonly affected anatomical site. That is explained by the anatomical features of the right main bronchus. Most bronchial foreign bodies do not present a need for urgent intervention. This study indicated that most cases required elective bronchoscopy. Out of all indications for bronchoscopy other than FB inhalation, including respiratory diseases, foreign body was found in one fifth of presented cases. This finding is an indication that FB inhalation may be asymptomatic and takes a period of time for symptoms to appear, clinically, FBs must be considered in any prolonged respiratory symptoms including cough and fever. In his study on 75 patients, Seghal observed that in 75 cases that underwent rigid bronchoscopy, 70 cases had positive tracheobroncheal foreign bodies, in 30% of these cases chest radiographs was non contributory (negative for FB findings), while 63% was distal emphysema⁽⁹⁾. In our study, the negative X-ray finding may be attributed to the early diagnosis and medical intervention before X-Ray detectable changes to the lung(s) occur. It may also be due to nature of foreign body, including small size.

Our study showed that a history of FB inhalation does not necessarily correlate with Bronchoscope findings for patients examined for FB inhalation. The difference between medical history and examination-based findings varied by one quarter. There was also considerable variations between x ray and bronchoscope findings. More than one third of negative x ray findings had positive foreign

body diagnosis by bronchoscope. Medical history and x ray were not sufficient on their own to exclude presence of FB in airways. Therefore, any suspicion should lead to an airway inspection (by bronchoscope), noting that the majority of aspirations are found in distal airways.

There was no mortality due to FB inhalation managed by rigid bronchoscope in ENT department at Shifa hospital compared to the available studies that figure (2%), despite the reported one mortality due to foreign body inhalation in 2003, thanks to Laryngeal-tracheal bronchoscope and the whole team in ENT department including: surgeons, anesthetists and nurses who assist and fully understand the equipment to perform bronchoscope safely and with minimal complications. The rigid bronchoscope is a potentially safe and effective tool for foreign body removal⁽¹⁰⁾. Management of FB inhalation is one of the successful services performed at the ENT department of Shifa hospital due to the early bronchoscope intervention.

Recommendations from this study:

- (a) To continue to using the same protocols for management of foreign body inhalation and better train all new doctors on diagnosis and management of foreign body inhalation.
- (b) Advise parents to avoid giving children under 6 years of age peanuts or other types of nuts, watermelon seeds, pins or other foreign bodies commonly swallowed by young children. This recommendation can be achieved by implementing community-based programs for awareness about foreign body inhalation among infants and children and how to prevent it.
- (c) Children with history of foreign body inhalation who present with symptoms of FBA,

must be referred to E N T department for bronchoscopy if the general condition is good for general anesthesia

(d) Children with history of foreign body inhalation presenting with severe respiratory distress must be referred for urgent bronchoscopy.

(e) Children with history of foreign body inhalation and no clinical or radiological signs of FBA must remain under observation and referred for E N T evaluation in out-patient clinic, if presenting with recurrent chest infection without apparent cause and e.g. bronchial asthma.

(f) Children presenting with unexplained respiratory disease must be referred for diagnostic bronchoscopy.

References:

- [1] Brian C. Spector, Endoscope and removal of foreign bodies, Current Opinion in Otolaryngology & Head and Neck Surgery 1998;6:416-420.
- [2] Martin E Warshawsky, Foreign body aspiration www.amadine.com/MED/topic 810.htm.
- [3] James B. Snow, JR. *Bronchology, Disease of the nose, throat, ear, head and neck*, Volume 2 Fourteenth edition 1991:1278-1296.
- [4] Sisenda, TM, Management of tracheo bronchial foreign bodies in children, East Afr-Med J. 2002 Nov;79(11):580-3.
- [5] J.N.G. Evans, Foreign bodies in the larynx and trachea, Scott-Browns Otolaryngology Sixth edition 1997:25:1-10.
- [6] Dunn, GR, Management of suspected foreign body aspiration in children, Clin-Otolaryngol, 2002 Oct;27(5):384-6.
- [7] Kosloske, AM, Bronchoscopic extraction of aspirated foreign bodies in children, Am-J-Dis-Child 1982 Oct;136(10):924-7.
- [8] Wasyl Szeremeta, Pediatric Otolaryngology 1999, Chapter 35:875-913.
- [9] Sehgal, A, Foreign body aspiration, Indian-Pediatr. 2002 Nov;39(11):1006-10.
- [10] Ibrahim Sersar S, Hamza UA, AbdelHameed WA, AbulMaaty RA, Gowaeli NN, Moussa SA, AlMorsi SM, Hafez MM. Inhaled foreign bodies: management according to early or late presentation. Eur. J. cardiothorac Surg. (2005) 28:369-7.

Acknowledgement: We thank *Annals of Alquds Medicine* for help with editing this manuscript.

* Corresponding Author: Dr. Samir Kuhail, Health research directorate, Ministry of Health, Gaza-Palestine. samirkuhail@yahoo.com.